

## REVIEW ARTICLE

Darren B. Taichman, M.D., Ph.D., *Editor*

## Cryptogenic Organizing Pneumonia

Talmadge E. King, Jr., M.D., and Joyce S. Lee, M.D.

From the University of California, San Francisco (T.E.K.); and the University of Colorado Anschutz Medical Campus, Aurora (J.S.L.). Dr. King can be contacted at [talmadge.king@ucsf.edu](mailto:talmadge.king@ucsf.edu) or at the School of Medicine, University of California San Francisco, 513 Parnassus Ave., Box 0410, San Francisco, CA 94143.

N Engl J Med 2022;386:1058-69.

DOI: 10.1056/NEJMra2116777

Copyright © 2022 Massachusetts Medical Society.

**CME**  
at **NEJM.org**

**O**RGANIZING PNEUMONIA IS A PATTERN OF LUNG-TISSUE REPAIR AFTER injury. It can be cryptogenic or a response to a specific lung injury and is also observed histopathologically in many diverse clinical contexts. Cryptogenic organizing pneumonia (COP) has no identifiable cause and is classified as a form of idiopathic interstitial pneumonia.<sup>1-4</sup> Formerly called bronchiolitis obliterans organizing pneumonia, this form is of clinical interest because it is often misdiagnosed, and when managed appropriately, it is associated with a high recovery rate. Secondary forms of organizing pneumonia are attributable to a specific cause (e.g., viral infection, drug toxicity, inhalation injury, radiation therapy, or cancer) or occur in association with a defined clinical context (e.g., connective-tissue disorder, aspiration, transplantation sequelae, or another interstitial pneumonia)<sup>5</sup> (Table 1).

## EPIDEMIOLOGY

COP has been reported worldwide; however, the exact incidence and prevalence are unknown. As compared with older case series,<sup>6,13</sup> more recent reports suggest lower rates of diagnosis,<sup>14,15</sup> perhaps because of increasing recognition of the causes of secondary forms of organizing pneumonia.<sup>5</sup> A nationwide retrospective study in Iceland showed that the mean annual incidence of COP was 1.10 cases per 100,000 persons over a 20-year period.<sup>16</sup> In a major teaching hospital in Canada, a cumulative prevalence of 6.7 cases per 100,000 hospital admissions was reported.<sup>13</sup> In registry studies of interstitial lung disease, the prevalence of COP was 5% in one study<sup>17</sup> and 10% in another.<sup>18</sup>

According to 37 published reports from centers around the world, which involved a total of 1490 patients with a confirmed diagnosis of COP, the mean age at diagnosis is 50 to 60 years (range, 17 to 95); COP is rarely reported in children.<sup>1,6-11,14,19-47</sup> The incidence of cases is slightly higher among men than among women (52% among men). Approximately 54% of patients with COP have never smoked, and 46% are former or current smokers; of former or current smokers, less than 15% reported that they smoked at the time of diagnosis. It has been suggested that environmental factors have a role in the initiation of COP.<sup>14,48</sup>

## PATHOPHYSIOLOGY

The pathogenesis of organizing pneumonia is poorly defined.<sup>2,3,5</sup> The lung injury appears to occur at a single moment and without major disruption of the lung's architecture. COP is an inflammatory and fibroproliferative process characterized by intraalveolar fibroproliferation that is reversible with (and occasionally without) immunosuppressive or antiinflammatory therapy. This pattern is in stark contrast to the pattern of other fibrotic processes, especially usual interstitial pneumonia (UIP), which is not reversible<sup>2,3</sup> (Fig. 1).

### ALVEOLAR INJURY

Early events in organizing pneumonia include localized denudation of the epithelial basal laminae and necrosis of type I alveolar epithelial cells, leading to gaps in the basal lamina.<sup>49,50</sup> The alveolar epithelial injury is followed by leakage of plasma proteins, fibrin formation, and migration of inflammatory cells (macrophages, lymphocytes, neutrophils, some eosinophils, and occasionally, plasma cells and mast cells) into the alveolar space<sup>50-52</sup> (Fig. 1A).

### ALVEOLAR ORGANIZATION

Fibroblasts are recruited to the alveolar lumen, where they proliferate, differentiate into myofibroblasts, and form the fibroinflammatory buds (Masson's bodies) that are characteristic of organizing pneumonia<sup>52</sup> (Fig. 1B). The fibroinflammatory buds are intermixed with a loose connective-tissue matrix that is rich in collagen (especially collagen I), fibronectin, procollagen type III, tenascin C, and proteoglycans.<sup>53,54</sup> Protein dysregulation, which involves vascular endothelial growth factor, basic fibroblast growth factor,<sup>55</sup> and matrix metalloproteinases (MMPs), occurs<sup>54,56</sup> and correlates with the angiogenic activity of the newly formed intraluminal fibromyxoid connective tissue in organizing pneumonia.<sup>57</sup>

### REMODELING

The inflammatory cells and fibrin deposits begin to disappear from the alveolar buds and are replaced by myofibroblasts organized in concentric rings alternating with layers of collagen bundles that consist of thin collagen I fibers, thinner fibrils of collagen and procollagen type III, and fibronectin.<sup>5,49</sup> The intraalveolar buds are remodeled into the interstitium, and collagen globules are formed<sup>54</sup> (Fig. 1C). The collagen globules contain densely arranged collagen fibrils and fibroblasts or myofibroblasts with cytoplasm, which contain actinlike microfilaments and phagocytosed collagen fibrils and are covered by type I alveolar epithelial cells with well-developed epithelial basement membranes. Alveolar epithelial cells proliferate and restore the continuity of the alveolar capillary membrane. The integrity and function of the alveolar unit are restored.<sup>5,49</sup>

In a minority of patients, a fibrosing pattern of organizing pneumonia, characterized by the presence of organizing pneumonia at the initial presentation, followed by nonspecific interstitial

**Table 1. Causes of Secondary Organizing Pneumonia.\***

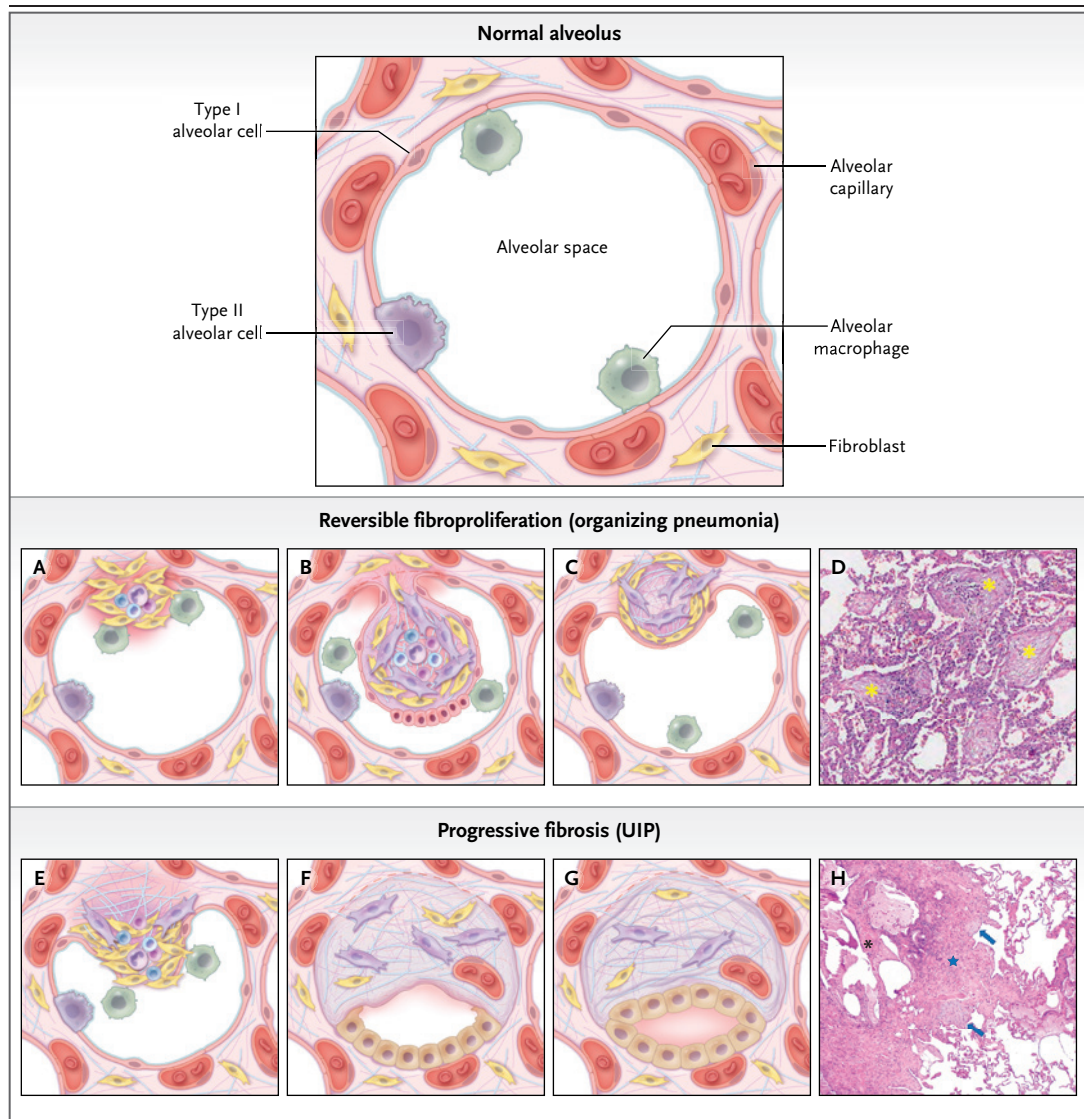
|  |
|--|
| Infection  |
| Bacteria: <i>Burkholderia cepacia</i> , <i>Chlamydia pneumoniae</i> , <i>Coxiella burnetii</i> , <i>Legionella pneumophila</i> , <i>Mycoplasma pneumoniae</i> , <i>Nocardia asteroides</i> , <i>Pseudomonas aeruginosa</i> , <i>Serratia marcescens</i> , <i>Staphylococcus aureus</i> , <i>Streptococcus pneumoniae</i> |
| Viruses: adenovirus, SARS-CoV-2, cytomegalovirus, herpesvirus, HIV, influenza virus, parainfluenza virus, HHV-7, RSV   |
| Parasites: <i>Plasmodium vivax</i> , <i>Dirofilaria immitis</i>  |
| Fungi: aspergillus, <i>Cryptococcus neoformans</i> , <i>Penicillium janthinellum</i> , <i>Pneumocystis jirovecii</i>   |
| Drugs: amiodarone, nitrofurantoin, bleomycin, methotrexate, freebase cocaine   |
| Connective-tissue disease: rheumatoid arthritis, Sjögren's syndrome, polymyositis or dermatomyositis, systemic sclerosis, antisynthetase syndrome, vasculitis  |
| Hematologic cancer: leukemia, lymphoma   |
| Transplantation: lung, liver, bone marrow  |
| Radiation injury from breast cancer treatment  |
| Common variable immunodeficiency   |
| Association with other interstitial lung diseases: eosinophilic pneumonia, hypersensitivity pneumonitis, organizing diffuse alveolar damage, usual interstitial pneumonia  |
| Inflammatory bowel disease: Crohn's disease, ulcerative colitis  |
| Miscellaneous causes   |
| Reaction to other lung processes: abscess, diffuse alveolar hemorrhage, airway obstruction   |
| Inhalation injury: aspiration, aerosolized textile dye, mustard gas  |

\* Information on secondary causes is from Cottin and Cordier,<sup>5</sup> Lohr et al.,<sup>6</sup> Boots et al.,<sup>7</sup> Chang et al.,<sup>8</sup> Barroso et al.,<sup>9</sup> Sveinsson et al.,<sup>10</sup> Drakopanagiotakis et al.,<sup>11</sup> and Wang et al.<sup>12</sup> HHV-7 denotes human herpesvirus 7, HIV human immunodeficiency virus, RSV respiratory syncytial virus, and SARS-CoV-2 severe acute respiratory syndrome coronavirus 2.

pneumonia many months later, has been reported.<sup>58,59</sup> The lung parenchymal remodeling is characterized by residual interstitial inflammation and fibrosis throughout the alveolar wall.<sup>59,60</sup> The alveolar architecture is preserved, and honeycomb change is uncommon. In addition, the failure to resorb the intraalveolar buds from the airspace into the interstitium and the failure to form collagen globules may account for the pattern of cicatricial organizing pneumonia (see the discussion below).<sup>43,61</sup>

### MASSON'S BODIES VERSUS FIBROBLASTIC FOCI

Several pathological features of organizing pneumonia distinguish it from other fibrotic lung processes such as UIP.<sup>62</sup> First, the pathological pattern of UIP represents an epithelial-driven



disorder associated with a complex interplay of genetic and environmental risk factors and aging-associated processes that involve fibroblast activation, abnormal epithelial and myofibroblast differentiation,<sup>63</sup> extracellular matrix remodeling, and finally, end-stage fibrosis.<sup>64</sup> Second, the alveolar epithelial injury with basement-membrane gaps, a crucial event that determines the intra-alveolar fibrotic involvement, is less extensive and less severe in organizing pneumonia.<sup>49</sup>

Third, recovery in organizing pneumonia is associated with reepithelialization surrounding the buds of loose connective tissue that contain inflammatory cells and fibroblasts.<sup>52,55</sup> Regenerating type II pneumocytes are layered in an orderly fashion and often have a flat shape reminiscent

of type I pneumocytes in organizing pneumonia, a process that differs from the disturbed or delayed epithelialization in UIP<sup>52,55</sup> (Fig. 1D). This recovery of alveolar epithelial cells, with restoration of the continuity of the alveolar capillary membrane and the sustained integrity of the alveolar unit, appears to be critical for the recovery and repair seen in organizing pneumonia.<sup>50,56,57,65</sup>

Fourth, although Masson's bodies in organizing pneumonia and fibroblastic foci in UIP share some morphologic features, the outcome of the disease process clearly differs between the two disorders.<sup>51</sup> In UIP, the fibroblastic foci appear to drive the irreversible fibrosing process, yet the fibromyxoid lesions in organizing pneumonia are reversible. The rate of fibroblast proliferation

**Figure 1 (facing page). Pathobiology of Reversible Fibroproliferation in Organizing Pneumonia and Progressive Fibrosis in Usual Interstitial Pneumonia (UIP).**

Shown at the top is a normal alveolus. Panel A shows alveolar injury in organizing pneumonia. Epithelial cell injury with denudation of the epithelial basal laminae leads to gaps, followed by leakage of plasma proteins, fibrin formation, and migration of inflammatory cells into the alveolar space. Panel B shows alveolar organization. The inflammatory cells and fibrin deposits do not obliterate the alveolar spaces, and they disappear from the alveolar buds. Activation, proliferation, and migration of the fibroblasts within the alveolar lumen through gaps in the basal lamina lead to the formation of fibroinflammatory buds (Masson's bodies). Capillaries, small fibroblasts (yellow), and myofibroblasts (lavender) in these edematous alveolar buds express a predominance of matrix metalloproteinases. Panel C shows remodeling. As resolution begins, fibroinflammatory buds are replaced by myofibroblasts organized in concentric rings alternating with layers of collagen bundles. The polyps are incorporated into the alveolar walls, and the collagen bundles (collagen globules) are covered with type I alveolar epithelial cells. These cells proliferate and restore the continuity of the alveolar capillary membrane and the integrity of the alveolar unit. The photomicrograph in Panel D (hematoxylin and eosin) shows the histologic features of organizing pneumonia at high magnification. Several polypoid intraluminal plugs of loose connective tissue are evident (asterisks). Mild, chronic inflammation is present in the alveolar walls. Panel E shows the effects of alveolar injury in UIP. Recurrent epithelial cell microinjuries result in increased vascular permeability to proteins (e.g., fibrinogen and fibronectin), causing the formation of a provisional matrix (wound clot). This is followed by bronchiolar and alveolar epithelial cell migration and proliferation into the intraalveolar space. Panel F shows the microenvironment of alveolar organization. Epithelial cells are abnormally activated and produce diverse growth factors and chemokines, which induce the migration of resident fibroblasts and bone marrow–derived progenitors of fibroblasts (fibrocytes) to the sites where the microinjuries are occurring. In addition, Panel G shows alveolar fibrosis, with differentiation of fibroblasts (yellow) to myofibroblasts (lavender) that accumulate in small collections and persist in the focus because of resistance to apoptosis. In the foci, myofibroblasts secrete excessive amounts of extracellular matrix proteins — mainly, fibrillar collagens — and express a predominance of tissue inhibitor of metalloproteinase 2. Alveolar collapse and progressive abnormal lung remodeling lead to cysts of various sizes surrounded by fibrosis with hyperplastic or bronchiolar-type epithelium (honeycombing). The photomicrograph in Panel H (hematoxylin and eosin) shows the histologic features of UIP at high magnification. Fibroblastic foci of loose, organizing connective tissue (arrows) are juxtaposed against marked fibrosis, which consist of dense collagenous scarring with remodeling of the lung architecture (star) and cystic changes (honeycombing) (black asterisk). An area of normal lung is present in the upper right portion of the panel.

is similar in the fibromyxoid lesions in organizing pneumonia and the fibroblastic foci in UIP. However, the apoptotic activity is increased in the intraalveolar buds in organizing pneumonia as compared with UIP.<sup>66</sup>

Fifth, the production, deposition, and proteolysis of the extracellular matrix (ECM) differ between UIP and organizing pneumonia.<sup>54,56</sup> MMPs and tissue inhibitors of metalloproteinases (TIMPs) are known to regulate remodeling of the ECM. The gelatinolytic activity of MMP-2 is significantly greater in organizing pneumonia than in normal lung tissues and UIP.<sup>54</sup> In UIP, the pulmonary structures are extensively remodeled and there is a predominance of TIMP-2, which suggests a role in promoting the irreversible deposition of ECM in the intraalveolar spaces.<sup>54,56</sup> Thus, the difference in the balance between proliferation and apoptosis in organizing pneumonia and UIP<sup>39,67,68</sup> and the presence of MMPs play key roles in the reversibility of the fibrotic lesions of organizing pneumonia.

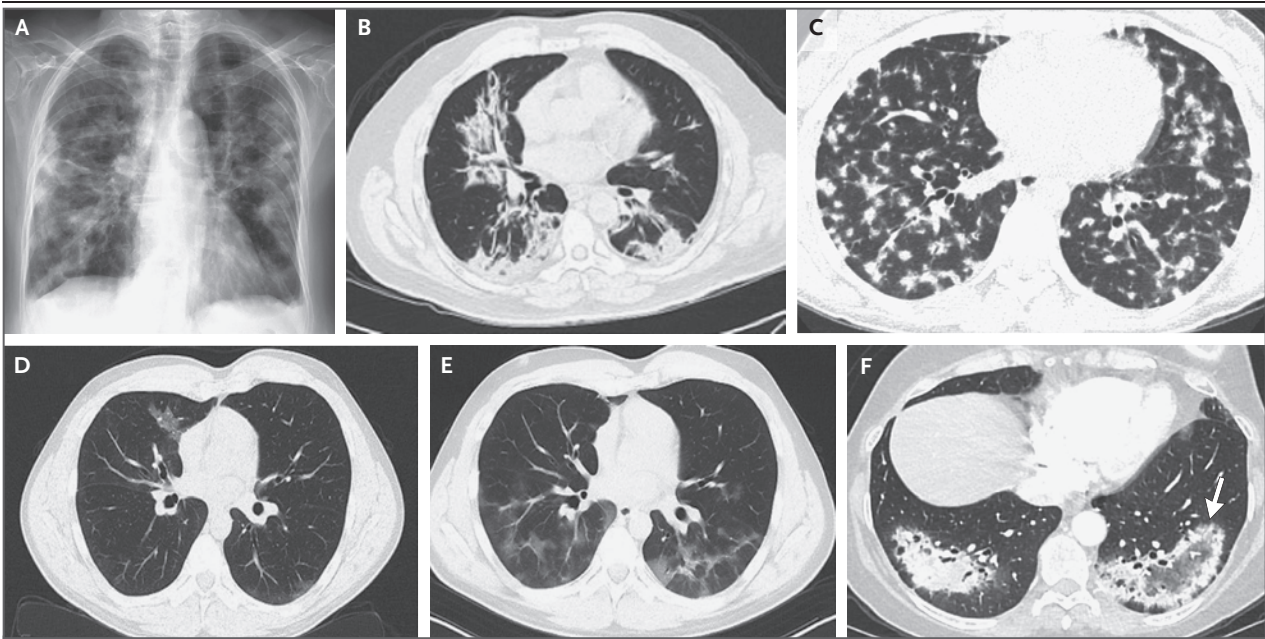
Finally, in UIP, the lung parenchyma is contracted and mechanically distorted by continued deposition of connective tissue and alveolar collapse.<sup>69</sup> Such deposition and alveolar collapse contribute to the permanent tissue remodeling observed in this disorder.<sup>51,70</sup>

#### CLINICAL PRESENTATION

COP is often suspected when patients with a presumed diagnosis of infectious pneumonia do not have a response to antibiotic treatment.<sup>6,9,13,27,36,47</sup> Symptoms of COP are often subacute and can emerge over a period of several weeks to several months.<sup>7,9,20,22,33,34,44,47</sup> Patients are often able to remember with some precision when their illness began. Common symptoms include dry cough (in 71% of reported cases) and dyspnea (in 62% of reported cases) that is mild to moderate and worsened by exertion.<sup>6-11,13,15,21,23,26,28-30,33-35,47</sup> Influenza-like symptoms (i.e., nasal congestion, headache, chills and sweats, sore throat, cough, fatigue, myalgia, and fever) have been reported in 10 to 15% of cases. Fever is present in 44% of cases of COP. The incidence of hemoptysis is very low (<5%).

The most common finding on physical examination is inspiratory crackles (in 60% of reported cases).<sup>1,6-11,19,20,26,29,33,34,44,45</sup> Clubbing is rare (reported in <3% of cases). The physical examination is normal in less than 5% of patients with COP.





**Figure 2.** Chest Radiograph and High-Resolution CT Images Showing Various Cryptogenic Organizing Pneumonia (COP) Patterns.

The posteroanterior radiograph of the chest in Panel A shows bilateral, diffuse, consolidative opacities in the presence of normal lung volumes. The high-resolution CT (HRCT) scan of the chest in Panel B shows peripheral and multifocal consolidation in the middle and lower lobes. The HRCT scan in Panel C shows diffuse peripheral nodules. The HRCT scans in Panels D and E show migratory opacities: a patchy, ground-glass opacity in the right upper lobe (Panel D) and new areas of patchy, ground-glass opacities in the same patient 1 month later (Panel E). The HRCT scan in Panel F shows the reversed halo, or atoll, sign, characterized by a rim of consolidation with more central clearing or ground-glass opacities (arrow).

## DIAGNOSTIC EVALUATION

A multidisciplinary approach, combining clinical, radiologic, and pathological expertise, is necessary to make the diagnosis of COP.<sup>2,3</sup>

### LABORATORY TESTING

The results of laboratory tests are nonspecific in patients with COP. However, inflammatory markers such as the erythrocyte sedimentation rate, C-reactive protein level, and leukocyte count are frequently elevated.<sup>6,7,9-11,21,23,27,30,33,34,37</sup> Patients with organizing pneumonia may present weeks to months before the development of an associated connective-tissue disorder.<sup>44</sup> Therefore, testing for these diseases (e.g., tests for antinuclear antibody, rheumatoid factor, anti-cyclic citrullinated peptide, creatine kinase, antitopoisomerase [anti-Scl-70] antibody, anticentromere antibody, anti-double-stranded DNA antibody, and anti-Jo-1 and other antisynthetase antibodies) is appropriate when a connective-tissue disorder is suspected.<sup>44</sup>

### PULMONARY-FUNCTION TESTING

Pulmonary-function tests often show a restrictive ventilatory defect and a reduced diffusing capacity for carbon monoxide.<sup>1,6,8,9,14,21,26,29,34,36,47</sup> Lung volumes are normal in up to 25% of patients with COP.<sup>11</sup> Airflow obstruction is not a feature, except among patients who have been or are smokers.<sup>6,7,24,71</sup> The lungs are stiff and non-compliant at diagnosis and return to normal in patients who have a response to treatment.<sup>71</sup> Arterial hypoxemia at rest and during exercise is common.<sup>8,9,11,14,21,23</sup>

### RADIOLOGIC STUDIES

The radiologic findings in COP are diverse. The manifestations of COP on a chest radiograph are typically distinctive, with bilateral opacities that are patchy or diffuse and consolidative or hazy, in the presence of normal lung volumes<sup>1,6,8-10,20-22,26,38</sup> (Fig. 2A).

The extent and severity of the process are much more evident on high-resolution computed tomographic (CT) lung scans, which often reveal

more extensive disease than can be seen on a review of the plain chest radiograph. The predominant pattern on high-resolution CT studies is peripheral and multifocal consolidation (with or without air bronchograms).<sup>10,14,23,26,29,33,34,41,45,47,72,73</sup> The findings may be unilateral or bilateral. The lesions are found in all lung zones, with a slightly predominant subpleural and lower-lung-zone distribution<sup>14,44-46,72</sup> (Fig. 2B). Other radiologic findings include ground-glass opacities; nodules that are approximately 8 mm in diameter, arranged in a well-defined acinar pattern, or smaller nodules in a more subtle, poorly defined pattern<sup>74</sup> (Fig. 2C); a peribronchovascular pattern, with areas of consolidation surrounding the bronchovascular bundles<sup>74</sup>; a linear and band-like pattern, with subpleural opacities that are parallel or perpendicular to the pleura<sup>73,74</sup>; and focal lesions.<sup>14,33,72</sup> Occasionally, the lesions are distributed in a perilobular pattern, characterized by poorly defined, bowed, or polygonal opacities, and are predominantly subpleural and surrounded by aerated lung.<sup>73</sup> Radiologic abnormalities can also be manifested as migratory opacities with areas of spontaneous regression and new areas of consolidation<sup>4,7,9,20,21,23,34,36,41</sup> (Fig. 2D and 2E). The reversed halo (or atoll) sign, characterized by a rim of consolidation with more central clearing or ground-glass opacities, is observed in less than 5% of cases and appears to be relatively specific for organizing pneumonia<sup>14,41,46,47,75</sup> (Fig. 2F). Mediastinal lymphadenopathy is rare.<sup>14,46,47,72</sup> Small pleural effusions have been reported in rare cases.<sup>6,9,11,14,23,41,45,46,72,75</sup>

On follow-up high-resolution CT, the finding of consolidation is associated with partial or complete resolution of the parenchymal abnormalities, whereas reticular opacities may be persistent or progressive.<sup>35,45</sup> A progressive fibrotic pattern and honeycombing changes are very rarely seen.<sup>59,72</sup> Despite the variation in radiologic findings, the presence of bilateral alveolar opacities in a relevant clinical context can support a diagnosis of organizing pneumonia.

#### BRONCHOALVEOLAR LAVAGE ANALYSIS

Analysis of a bronchoalveolar lavage (BAL) specimen is recommended if COP is suspected, in order to rule out infection and other disorders, such as eosinophilic pneumonia and alveolar hemorrhage. Cellular analysis of a BAL specimen often shows a lymphocytic alveolitis associ-

ated with an increase in neutrophil and eosinophil counts.<sup>8,9,11,20-22,24,26,30,32,34,36,40,47,71,76</sup> However, the presence of these cell types should prompt an investigation for secondary causes of organizing pneumonia (e.g., hypersensitivity pneumonitis, infection, and eosinophilic pneumonia). Normalization of BAL findings lags behind improvements in clinical and radiologic findings.<sup>76</sup>

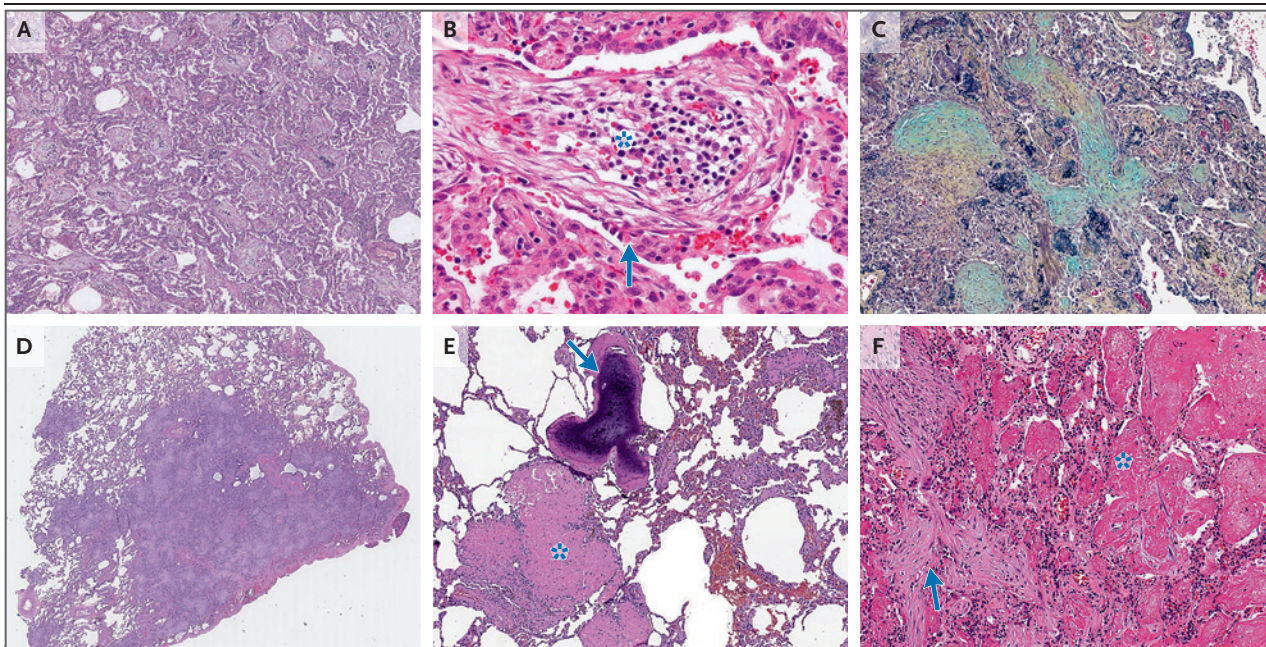
#### HISTOPATHOLOGICAL ASSESSMENT

COP can often be managed without histopathological confirmation. In some cases, however, tissue studies may be needed to confirm the diagnosis. The decision to perform a biopsy should be guided by a multidisciplinary discussion. Histologic changes may suggest an underlying cause of secondary organizing pneumonia (e.g., aspiration, vasculitis, or infections).<sup>60</sup> In cases managed without a biopsy, if the clinical follow-up is not consistent with the diagnosis of COP, the diagnosis should be reevaluated, and a biopsy may be necessary.

Histopathological examination of a lung-biopsy specimen from a patient with COP reveals intraluminal plugs of loose connective tissue that involve alveolar spaces and alveolar ducts and may also involve bronchioles<sup>19</sup> (Fig. 3A and 3B). The underlying architecture of the lung is preserved. The intraluminal plugs of loose connective tissue are often connected to alveolar walls by narrow stalks and extend from one alveolus to the adjacent one through the pores of Kohn, giving rise to a characteristic butterfly pattern<sup>52</sup> (Fig. 3C). Mild, chronic inflammation (involving lymphocytes and plasma cells, for example) may be present in the alveolar walls. However, a finding of prominent interstitial chronic inflammation (involving neutrophils or eosinophils<sup>77</sup>), poorly formed granulomas, peribronchiolar metaplasia, lymphoid aggregates, vasculitis, interstitial fibrosis, or microscopic honeycombing should suggest an alternative diagnosis.

The histologic pattern of organizing pneumonia can be recognized in small biopsy specimens such as transbronchial or core biopsy specimens. However, the smaller the specimen, the more difficult it is to identify all the features of the pattern. Moreover, sampling problems are more likely with small specimens. For this reason, correlation of the findings in lung-biopsy specimens, including surgical specimens, with CT findings is important to help determine whether





**Figure 3. Histopathological Features of COP.**

The low-magnification photomicrograph in Panel A (hematoxylin and eosin) shows multiple variously shaped, intraluminal plugs of loose connective tissue. The intervening alveolar walls show mild thickening by an inflammatory infiltrate, but the lung architecture is otherwise preserved, without features of established fibrosis. The high-magnification photomicrograph in Panel B (hematoxylin and eosin) shows an intraluminal fibromyxoid lesion with a cluster of inflammatory cells (asterisk), and regenerating epithelial cells, some with a flat shape that is consistent with type 1 pneumocytes, cover the surface of the bud (arrow). The high-magnification photomicrograph in Panel C (pentachrome stain) shows an intraluminal plug of loose connective tissue (green) that extends from one alveolus to the adjacent one through the pores of Kohn (butterfly pattern). Mild inflammation is present in the alveolar walls and surrounding parenchyma. The low-magnification photomicrograph in Panel D (hematoxylin and eosin) shows a focal organizing pneumonia lesion that was surgically resected. The low-magnification photomicrograph in Panel E (hematoxylin and eosin) shows cicatricial organizing pneumonia with densely hyalinized and fibrotic luminal plugs (asterisk) and metaplastic bone formation (arrow) associated with preservation of the underlying lung architecture. The high-magnification photomicrograph in Panel F (hematoxylin and eosin) shows acute fibrinous and organizing pneumonia characterized by intraalveolar fibrin in the form of balls (asterisk) and intraluminal fibromyxoid lesions of organizing pneumonia (arrow).

the biopsy specimen is representative of the interstitial process.<sup>6,13</sup> Microscopic examination of small biopsy specimens with the use of serial step sectioning has been proposed as a way to increase the chance of detecting the organizing pneumonia pattern.<sup>78</sup>

#### VARIANTS

##### FOCAL ORGANIZING PNEUMONIA

Focal organizing pneumonia is relatively rare (diagnosed in <15% of patients with COP), and patients are often asymptomatic<sup>6,14,32,36,43,44</sup> (Fig. 3D). Surgical resection of a solitary lesion is usually curative.<sup>6,14,32,36,43,44</sup> Focal organizing pneumonia must be distinguished from lung cancer.

##### FULMINANT DISEASE

A subset of patients with organizing pneumonia present with a rapidly progressive clinical course

(e.g., requiring high-flow supplemental oxygen and progressing to mechanical ventilation).<sup>8,30,59</sup> In such cases, it is important to rule out a secondary cause, especially infection, connective-tissue disease, autoimmune disease, exposure to drugs or environmental agents, diffuse alveolar damage, or acute exacerbation of interstitial lung disease.<sup>59</sup> After infection has been ruled out, intravenous glucocorticoid therapy is recommended.<sup>59</sup> Respiratory failure is the primary cause of death, which usually occurs within 30 to 50 days after hospitalization.<sup>8,59</sup>

##### CICATRICIAL ORGANIZING PNEUMONIA

In a subset of cases of organizing pneumonia, the airspaces are filled with loose, fibromyxoid connective tissue associated with the formation of intraluminal, dense eosinophilic fibrosis and preservation of the underlying lung architecture.<sup>43,79</sup> Areas of linear fibrous bands and meta-

plastic bone formation in the lung parenchyma (dendriform ossification) may be present<sup>43,61,79</sup> (Fig. 3E). The cicatricial variant appears to be predictive of fibrotic nonspecific interstitial pneumonia, which is a more recalcitrant form of organizing pneumonia that should be morphologically separated from classic COP.<sup>26,61,79</sup>

#### ACUTE FIBRINOUS AND ORGANIZING PNEUMONIA

A rare alveolar filling disease, acute fibrinous organizing pneumonia, is characterized by a patchy distribution<sup>80,81</sup> (Fig. 3F). This variant can be idiopathic or associated with other processes, such as diffuse alveolar damage, hypersensitivity pneumonitis, infection, drug toxicity, eosinophilic pneumonia, and connective-tissue disease.<sup>80-83</sup>

#### DIFFERENTIAL DIAGNOSIS

The differential diagnosis of COP includes a broad spectrum of diseases that have similar clinical and radiologic features. The most important mimic of COP is community-acquired pneumonia. Often, it is the absence of a response to antibiotic treatment that suggests COP. The following clinical processes associated with fluctuating, multifocal, parenchymal consolidation on radiologic studies should be considered: hypersensitivity pneumonitis (exposure to a known etiologic agent), eosinophilic pneumonia (elevated blood or alveolar eosinophil levels), alveolar hemorrhage (hemoptysis), and vasculitis (presence of antineutrophil cytoplasmic antibody). Pulmonary lymphoma and invasive mucinous adenocarcinoma may have a radiologic appearance similar to that of COP (patchy, nodular areas of consolidation with an air bronchogram). The concurrent or sequential presentation of organizing pneumonia and nonspecific interstitial pneumonia should trigger a search for an underlying cause (e.g., connective-tissue disease, antisynthetase syndrome, hypersensitivity pneumonitis, or drug toxicity).

#### TREATMENT

Treatment of COP is empirical because no prospective, randomized treatment trials have been performed. A decision to initiate therapy and the choice of therapy depend on the severity of the clinical, physiological, and radiologic abnormalities at presentation and the rapidity of disease progression. Spontaneous improvement has been

reported (in <10% of patients), mainly in patients who have mild disease (few symptoms and a limited extent of disease) or contraindications or who have declined therapy.<sup>1,10,11,14,20,21,23,32,35,44</sup>

#### GLUCOCORTICOID THERAPY

Systemic glucocorticoid therapy is the preferred treatment for symptomatic patients with respiratory impairment due to COP.<sup>8,9,14,23,24,26,30,44,71</sup> The usual starting dose is 0.5 to 1 mg of prednisone per kilogram of body weight per day (on the basis of ideal body weight), up to a maximum of 60 mg per day, given as a single oral dose in the morning. This initial dose is given for 2 to 4 weeks. Depending on the clinical response, the dose is tapered to 0.25 mg per kilogram per day to complete 4 to 6 months of therapy. Over the next 6 to 12 months, the oral glucocorticoid dose is gradually tapered to zero if the patient's condition remains stable or improves.

Glucocorticoid therapy usually induces clinical improvement, beginning within 24 to 72 hours.<sup>14,32</sup> Patients usually have decreased symptoms, followed by resolution of the radiologic findings within 3 months after diagnosis.<sup>6,13,14,76</sup> *Pneumocystis jirovecii* prophylaxis is recommended with doses of prednisone higher than 20 mg per day. For patients with severe or rapidly progressive disease and impending respiratory failure, high-dose glucocorticoid therapy with methylprednisolone (500 to 1000 mg administered intravenously each day for 3 to 5 days) may be required, with a transition to oral therapy once the patient's condition improves (typically within several days).<sup>45</sup>

Relapse (i.e., worsening symptoms or the appearance of characteristic new opacities or the worsening of residual shadows on chest CT scans obtained during or after glucocorticoid treatment) has been reported in less than 25% of cases, usually within the first year after the initial presentation.<sup>1,6,7,9-11,14,15,23,27,35,38,44,45</sup> Relapses can occur when treatment is tapered or stopped too quickly.<sup>7,27,38,44</sup> Most relapses occur when the prednisone dose is reduced to 15 mg per day or less. Several factors have been associated with relapse: delayed diagnosis<sup>14,38</sup>; delayed initiation of treatment (>2 months after the onset of symptoms)<sup>38,45</sup>; severe disease, including multifocal opacities<sup>9,42,44,46</sup>; the presence of traction bronchiectasis on chest imaging<sup>45</sup>; abnormal diffusing capacity for carbon monoxide (<50% of the predicted value)<sup>44</sup>; the presence of cholestasis<sup>38,48</sup>;



hypoxemia (partial pressure of arterial oxygen, <70 mm Hg)<sup>27</sup>; and histopathological findings of intraalveolar fibrin<sup>37,42</sup> or scarring and remodeling of the background lung parenchyma.<sup>25</sup>

Relapses are commonly treated by resuming or increasing glucocorticoid treatment. One study showed that treatment of relapse with lower doses of a glucocorticoid ( $\leq 20$  mg per day) resulted in lower cumulative doses and lower rates of side effects than a higher dose, with a similar objective benefit.<sup>38</sup> Relapse has not been associated with increased morbidity or mortality among patients with COP.<sup>14,38,44,46</sup>

#### OTHER THERAPIES

An alternative agent can be considered for patients in whom the initial therapy with systemic glucocorticoids does not result in clinical improvement or for those in whom glucocorticoids cannot be tapered to a safe level that is free of unacceptable adverse effects.

##### *Macrolide Antibiotics*

Case reports and small, retrospective series have suggested that macrolide antibiotics with anti-inflammatory properties (e.g., erythromycin or clarithromycin) might be a useful adjunct or alternative to oral glucocorticoid therapy in patients with COP.<sup>1,11,28,44,84</sup> Macrolide treatment is usually administered for 3 to 6 months or longer, with close monitoring during withdrawal of treatment to prevent relapse. Unfortunately, macrolides appear to be less effective than glucocorticoids.

##### *Cytotoxic Therapy*

Azathioprine or cyclophosphamide is not recommended in patients with COP except in very rare cases in which other approaches have failed.<sup>8,28,30,31,59,71</sup> For patients with normal renal function, the initial dose of azathioprine is 1 to 2 mg per kilogram per day (given as a single oral daily dose), up to a maximum of 150 mg per day. The recommendation is to start at a dose of 50 mg daily and slowly increase the dose over a period of 2 to 4 weeks, with treatment continued for at least 3 months. Given the toxic effects associated with cyclophosphamide, therapy should be discontinued after 6 months.<sup>71</sup>

##### *Mycophenolate Mofetil and Other Agents*

Mycophenolate mofetil, an inhibitor of proliferating lymphocytes, is increasingly used as a glu-

cocorticoid-sparing agent in the treatment of fibrotic lung disease, including COP.<sup>31,81</sup> In case reports, cyclosporine,<sup>85,86</sup> rituximab,<sup>87</sup> and intravenous immune globulin<sup>88</sup> have been used with limited success (usually in combination with glucocorticoids) to treat rapidly progressive disease or glucocorticoid-resistant organizing pneumonia.

#### PROGNOSIS

The prognosis and response to treatment for patients with COP are generally excellent. Patients with radiologic airspace opacities have much better outcomes than those with reticular opacities.<sup>23,25,35,46</sup> For patients who are hospitalized, the length of stay is usually less than 3 weeks, and improvement is generally rapid (often within 72 hours and rarely >10 days) after diagnosis and initiation of glucocorticoid treatment.<sup>14</sup>

Progressive respiratory failure requiring mechanical ventilation and resulting in death is rare in patients with organizing pneumonia.<sup>6,16,30</sup> In most retrospective studies, death from COP occurs in less than 10% of cases and the cause of death is most often unrelated to COP.<sup>1,6-11,14,19-21,23-32,34-38,41-46</sup> The 5-year survival rate exceeds 90%. However, the mortality rate among patients with COP is higher than that in the general population.<sup>6,16</sup> Death is more commonly reported among patients with secondary organizing pneumonia, usually as a result of the underlying illness.<sup>6,14,27</sup>

#### FUTURE DIRECTIONS

The incidence and prevalence of COP remain poorly defined. Given the improved definition of the disorder, however, ongoing, prospective collection of data from idiopathic interstitial pneumonia registries should clarify this issue. More studies are needed to distinguish primary COP from secondary organizing pneumonia. The dose and duration of glucocorticoid therapy remain poorly defined, and the usefulness of immunosuppressive therapy as primary or secondary treatment is unknown. Deciphering the cellular and molecular mechanisms underlying the development and resolution of organizing pneumonia may allow for greater progress in identifying risk factors and appropriate therapeutic strategies for the unrelentingly progressive and

irreversible fibrotic lesion in UIP. In particular, an understanding of the difference between fibroblastic foci and Masson's bodies may lead to identification of better diagnostic and therapeutic approaches to organizing pneumonia and UIP.

Disclosure forms provided by the authors are available with the full text of this article at NEJM.org.

We thank Drs. Carlyne Cool, William Travis, and Jian Jing for their advice and comments about histopathological features of COP and histologic images, and Drs. Brett Elicker and Tami Bang for the chest imaging studies.

## REFERENCES

- Epler GR, Colby TV, McLoud TC, Carrington CB, Gaensler EA. Bronchiolitis obliterans organizing pneumonia. *N Engl J Med* 1985;312:152-8.
- American Thoracic Society; European Respiratory Society. American Thoracic Society/European Respiratory Society international multidisciplinary consensus classification of the idiopathic interstitial pneumonias. This joint statement of the American Thoracic Society (ATS), and the European Respiratory Society (ERS) was adopted by the ATS board of directors, June 2001 and by the ERS executive committee, June 2001. *Am J Respir Crit Care Med* 2002;165:277-304.
- Travis WD, Costabel U, Hansell DM, et al. An official American Thoracic Society/European Respiratory Society statement: update of the international multidisciplinary classification of the idiopathic interstitial pneumonias. *Am J Respir Crit Care Med* 2013;188:733-48.
- Davison AG, Heard BE, McAllister WA, Turner-Warwick ME. Cryptogenic organizing pneumonitis. *Q J Med* 1983;52:382-94.
- Cottin V, Cordier J-F. Cryptogenic organizing pneumonia. *Semin Respir Crit Care Med* 2012;33:462-75.
- Lohr RH, Bolland BJ, Douglas WW, et al. Organizing pneumonia. Features and prognosis of cryptogenic, secondary, and focal variants. *Arch Intern Med* 1997;157:1323-9.
- Boots RJ, McEvoy JD, Mowat P, Le Fevre I. Bronchiolitis obliterans organising pneumonia: a clinical and radiological review. *Aust N Z J Med* 1995;25:140-5.
- Chang J, Han J, Kim DW, et al. Bronchiolitis obliterans organizing pneumonia: clinicopathologic review of a series of 45 Korean patients including rapidly progressive form. *J Korean Med Sci* 2002;17:179-86.
- Barroso E, Hernandez L, Gil J, Garcia R, Aranda I, Romero S. Idiopathic organizing pneumonia: a relapsing disease. 19 years of experience in a hospital setting. *Respiration* 2007;74:624-31.
- Sveinsson OA, Isaksson HJ, Sigvaldason A, Yngvason F, Aspelund T, Gudmundsson G. Clinical features in secondary and cryptogenic organising pneumonia. *Int J Tuberc Lung Dis* 2007;11:689-94.
- Drakopanagiotakis F, Paschalaki K, Abu-Hijleh M, et al. Cryptogenic and secondary organizing pneumonia: clinical presentation, radiographic findings, treatment response, and prognosis. *Chest* 2011;139:893-900.
- Wang Y, Jin C, Wu CC, et al. Organizing pneumonia of COVID-19: time-dependent evolution and outcome in CT findings. *PLoS One* 2020;15(11):e0240347.
- Alasaly K, Muller N, Ostrow DN, Champion P, FitzGerald JM. Cryptogenic organizing pneumonia. A report of 25 cases and a review of the literature. *Medicine (Baltimore)* 1995;74:201-11.
- Zhang Y, Li N, Li Q, et al. Analysis of the clinical characteristics of 176 patients with pathologically confirmed cryptogenic organizing pneumonia. *Ann Transl Med* 2020;8:763.
- Vieira AL, Vale A, Melo N, et al. Organizing pneumonia revisited: insights and uncertainties from a series of 67 patients. *Sarcoidosis Vasc Diffuse Lung Dis* 2018;35:129-38.
- Gudmundsson G, Sveinsson O, Isaksson HJ, Jonsson S, Frodadottir H, Aspelund T. Epidemiology of organising pneumonia in Iceland. *Thorax* 2006;61:805-8.
- Karakatsani A, Papakosta D, Rapti A, et al. Epidemiology of interstitial lung diseases in Greece. *Respir Med* 2009;103:1122-9.
- Xaubet A, Ancochea J, Morell F, et al. Report on the incidence of interstitial lung diseases in Spain. *Sarcoidosis Vasc Diffuse Lung Dis* 2004;21:64-70.
- Guerry-Force ML, Müller NL, Wright JL, et al. A comparison of bronchiolitis obliterans with organizing pneumonia, usual interstitial pneumonia, and small airways disease. *Am Rev Respir Dis* 1987;135:705-12.
- Nagai S, Aung H, Tanaka S, et al. Bronchoalveolar lavage cell findings in patients with BOOP and related diseases. *Chest* 1992;102:Suppl:32S-37S.
- Izumi T, Kitaichi M, Nishimura K, Nagai S. Bronchiolitis obliterans organizing pneumonia. Clinical features and differential diagnosis. *Chest* 1992;102:715-9.
- Costabel U, Teschler H, Guzman J. Bronchiolitis obliterans organizing pneumonia (BOOP): the cytological and immunocytological profile of bronchoalveolar lavage. *Eur Respir J* 1992;5:791-7.
- Yamamoto M, Ina Y, Kitaichi M, Harasawa M, Tamura M. Clinical features of BOOP in Japan. *Chest* 1992;102:Suppl:21S-25S.
- Pesci A, Majori M, Piccoli ML, et al. Mast cells in bronchiolitis obliterans organizing pneumonia: mast cell hyperplasia and evidence for extracellular release of tryptase. *Chest* 1996;110:383-91.
- Yousem SA, Lohr RH, Colby TV. Idiopathic bronchiolitis obliterans organizing pneumonia/cryptogenic organizing pneumonia with unfavorable outcome: pathologic predictors. *Mod Pathol* 1997;10:864-71.
- Nagai S, Kitaichi M, Itoh H, Nishimura K, Izumi T, Colby TV. Idiopathic nonspecific interstitial pneumonia/fibrosis: comparison with idiopathic pulmonary fibrosis and BOOP. *Eur Respir J* 1998;12:1010-9.
- Watanabe K, Senju S, Wen FQ, Shirakusa T, Maeda F, Yoshida M. Factors related to the relapse of bronchiolitis obliterans organizing pneumonia. *Chest* 1998;114:1599-606.
- Basarakodu KR, Aronow WS, Nair CK, et al. Differences in treatment and in outcomes between idiopathic and secondary forms of organizing pneumonia. *Am J Ther* 2007;14:422-6.
- Vasu TS, Cavallazzi R, Hirani A, Sharma D, Weibel SB, Kane GC. Clinical and radiologic distinctions between secondary bronchiolitis obliterans organizing pneumonia and cryptogenic organizing pneumonia. *Respir Care* 2009;54:1028-32.
- Yoo J-W, Song JW, Jang SJ, et al. Comparison between cryptogenic organizing pneumonia and connective tissue disease-related organizing pneumonia. *Rheumatology (Oxford)* 2011;50:932-8.
- Todd NW, Marciniak ET, Sachdeva A, et al. Organizing pneumonia/non-specific interstitial pneumonia overlap is associated with unfavorable lung disease progression. *Respir Med* 2015;109:1460-8.
- Niksarlıoğlu EY, Özkan GZ, Bakan ND, Yurt S, Kılıç L, Çamsarı G. Cryptogenic organizing pneumonia: clinical and radiological features, treatment outcomes of 17 patients, and review of the literature. *Turk J Med Sci* 2016;46:1712-8.
- Yılmaz S, Akıncı Özyürek B, Erdoğan Y, et al. Retrospective evaluation of patients with organizing pneumonia: is cryptogenic organizing pneumonia different from secondary organizing pneumonia? *Tuberk Toraks* 2017;65:1-8.
- Baha A, Yıldırım F, Köktürk N, et al. Cryptogenic and secondary organizing pneumonia: clinical presentation, radiological and laboratory findings, treatment, and prognosis in 56 cases. *Turk Thorac J* 2018;19:201-8.
- Chung MP, Nam BD, Lee KS, et al. Serial chest CT in cryptogenic organizing pneumonia: evolutionary changes and prognostic determinants. *Respirology* 2018;23:325-30.

36. Cordier JF, Loire R, Brune J. Idiopathic bronchiolitis obliterans organizing pneumonia: definition of characteristic clinical profiles in a series of 16 patients. *Chest* 1989;96:999-1004.
37. Yoshinouchi T, Ohtsuki Y, Kubo K, Shikata Y. Clinicopathological study on two types of cryptogenic organizing pneumonitis. *Respir Med* 1995;89:271-8.
38. Lazor R, Vandevenne A, Pelletier A, Leclerc P, Court-Fortune I, Cordier JF. Cryptogenic organizing pneumonia. Characteristics of relapses in a series of 48 patients. The Groupe d'Etudes et de Recherche sur les Maladies "Orphelines" Pulmonaires (GERM"O"p). *Am J Respir Crit Care Med* 2000;162:571-7.
39. Chung WY, Sun JS, Park JH, et al. Epithelial apoptosis as a clinical marker in idiopathic interstitial pneumonia. *Respir Med* 2010;104:1722-8.
40. Jara-Palomares L, Gomez-Izquierdo L, Gonzalez-Vergara D, et al. Utility of high-resolution computed tomography and BAL in cryptogenic organizing pneumonia. *Respir Med* 2010;104:1706-11.
41. Pardo J, Panizo A, Sola I, Queipo F, Martinez-Peñuela A, Carias R. Prognostic value of clinical, morphologic, and immunohistochemical factors in patients with bronchiolitis obliterans-organizing pneumonia. *Hum Pathol* 2013;44:718-24.
42. Nishino M, Mathai SK, Schoenfeld D, Digumarthy SR, Kradin RL. Clinicopathologic features associated with relapse in cryptogenic organizing pneumonia. *Hum Pathol* 2014;45:342-51.
43. Yousem SA. Cicatricial variant of cryptogenic organizing pneumonia. *Hum Pathol* 2017;64:76-82.
44. Zhou Y, Wang L, Huang M, et al. A long-term retrospective study of patients with biopsy-proven cryptogenic organizing pneumonia. *Chron Respir Dis* 2019;16:1479973119853829.
45. Saito Z, Kaneko Y, Hasegawa T, et al. Predictive factors for relapse of cryptogenic organizing pneumonia. *BMC Pulm Med* 2019;19:10.
46. Cho YH, Chae EJ, Song JW, Do K-H, Jang SJ. Chest CT imaging features for prediction of treatment response in cryptogenic and connective tissue disease-related organizing pneumonia. *Eur Radiol* 2020;30:2722-30.
47. Choi K-J, Yoo E-H, Kim KC, Kim EJ. Comparison of clinical features and prognosis in patients with cryptogenic and secondary organizing pneumonia. *BMC Pulm Med* 2021;21:336.
48. Spiteri MA, Klenerman P, Sheppard MN, Padley S, Clark TJ, Newman-Taylor A. Seasonal cryptogenic organising pneumonia with biochemical cholestasis: a new clinical entity. *Lancet* 1992;340:281-4.
49. Peyrol S, Cordier JF, Grimaud JA. Intralveolar fibrosis of idiopathic bronchiolitis obliterans-organizing pneumonia. Cell-matrix patterns. *Am J Pathol* 1990;137:155-70.
50. Myers JL, Katzenstein AL. Ultrastructural evidence of alveolar epithelial injury in idiopathic bronchiolitis obliterans-organizing pneumonia. *Am J Pathol* 1988;132:102-9.
51. Kuhn C, McDonald JA. The roles of the myofibroblast in idiopathic pulmonary fibrosis. Ultrastructural and immunohistochemical features of sites of active extracellular matrix synthesis. *Am J Pathol* 1991;138:1257-65.
52. Basset F, Ferrans VJ, Soler P, Take-mura T, Fukuda Y, Crystal RG. Intraluminal fibrosis in interstitial lung disorders. *Am J Pathol* 1986;122:443-61.
53. Kuhn C III, Boldt J, King TE Jr, Crouch E, Vartio T, McDonald JA. An immunohistochemical study of architectural remodeling and connective tissue synthesis in pulmonary fibrosis. *Am Rev Respir Dis* 1989;140:1693-703.
54. Fukuda Y, Ishizaki M, Kudoh S, Kitaichi M, Yamanaka N. Localization of matrix metalloproteinases-1, -2, and -9 and tissue inhibitor of metalloproteinase-2 in interstitial lung diseases. *Lab Invest* 1998;78:687-98.
55. Lappi-Blanco E, Kaarteenaho-Wiik R, Salo S, et al. Laminin-5 gamma2 chain in cryptogenic organizing pneumonia and idiopathic pulmonary fibrosis. *Am J Respir Crit Care Med* 2004;169:27-33.
56. Choi KH, Lee HB, Jeong MY, et al. The role of matrix metalloproteinase-9 and tissue inhibitor of metalloproteinase-1 in cryptogenic organizing pneumonia. *Chest* 2002;121:1478-85.
57. Lappi-Blanco E, Kaarteenaho-Wiik R, Soini Y, Risteli J, Pääkkö P. Intraluminal fibromyxoid lesions in bronchiolitis obliterans organizing pneumonia are highly capillarized. *Hum Pathol* 1999;30:1192-6.
58. Lee JW, Lee KS, Lee HY, et al. Cryptogenic organizing pneumonia: serial high-resolution CT findings in 22 patients. *Am J Roentgenol* 2010;195:916-22.
59. Cohen AJ, King TE Jr, Downey GP. Rapidly progressive bronchiolitis obliterans with organizing pneumonia. *Am J Respir Crit Care Med* 1994;149:1670-5.
60. Beardsley B, Rassl D. Fibrosing organising pneumonia. *J Clin Pathol* 2013;66:875-81.
61. Churg A, Wright JL, Bilawich A. Cicatricial organising pneumonia mimicking a fibrosing interstitial pneumonia. *Histopathology* 2018;72:846-54.
62. Selman M, King TE, Pardo A. Idiopathic pulmonary fibrosis: prevailing and evolving hypotheses about its pathogenesis and implications for therapy. *Ann Intern Med* 2001;134:136-51.
63. Chilosi M, Calìo A, Rossi A, et al. Epithelial to mesenchymal transition-related proteins ZEB1,  $\beta$ -catenin, and  $\beta$ -tubulin-III in idiopathic pulmonary fibrosis. *Mod Pathol* 2017;30:26-38.
64. Selman M, Pardo A. From pulmonary fibrosis to progressive pulmonary fibrosis: a lethal pathobiological jump. *Am J Physiol Lung Cell Mol Physiol* 2021;321(3):L600-L607.
65. Lee JS, La J, Aziz S, et al. Molecular markers of telomere dysfunction and senescence are common findings in the usual interstitial pneumonia pattern of lung fibrosis. *Histopathology* 2021;79:67-76.
66. Lappi-Blanco E, Soini Y, Pääkkö P. Apoptotic activity is increased in the newly formed fibromyxoid connective tissue in bronchiolitis obliterans organizing pneumonia. *Lung* 1999;177:367-76.
67. Kuwano K, Kawasaki M, Maeyama T, et al. Soluble form of fas and fas ligand in BAL fluid from patients with pulmonary fibrosis and bronchiolitis obliterans organizing pneumonia. *Chest* 2000;118:451-8.
68. Ye Q, Dai H, Sarria R, Guzman J, Costabel U. Increased expression of tumor necrosis factor receptors in cryptogenic organizing pneumonia. *Respir Med* 2011;105:292-7.
69. McDonald JA. Idiopathic pulmonary fibrosis. A paradigm for lung injury and repair. *Chest* 1991;99:Suppl:87S-93S.
70. Myers JL, Katzenstein AL. Epithelial necrosis and alveolar collapse in the pathogenesis of usual interstitial pneumonia. *Chest* 1988;94:1309-11.
71. King TE Jr, Mortenson RL. Cryptogenic organizing pneumonitis. The North American experience. *Chest* 1992;102:Suppl:8S-13S.
72. Lee KS, Kullnig P, Hartman TE, Müller NL. Cryptogenic organizing pneumonia: CT findings in 43 patients. *Am J Roentgenol* 1994;162:543-6.
73. Ujita M, Renzoni EA, Veeraraghavan S, Wells AU, Hansell DM. Organizing pneumonia: peribular pattern at thin-section CT. *Radiology* 2004;232:757-61.
74. Oikonomou A, Hansell DM. Organizing pneumonia: the many morphological faces. *Eur Radiol* 2002;12:1486-96.
75. Kim SJ, Lee KS, Ryu YH, et al. Reversed halo sign on high-resolution CT of cryptogenic organizing pneumonia: diagnostic implications. *Am J Roentgenol* 2003;180:1251-4.
76. Costabel U, Teschler H, Schoenfeld B, et al. BOOP in Europe. *Chest* 1992;102:Suppl:14S-20S.
77. Olopade CO, Crotty TB, Douglas WW, Colby TV, Sur S. Chronic eosinophilic pneumonia and idiopathic bronchiolitis obliterans organizing pneumonia: comparison of eosinophil number and degranulation by immunofluorescence staining for eosinophil-derived major basic protein. *Mayo Clin Proc* 1995;70:137-42.



78. Nagata N, Hirano H, Takayama K, Miyagawa Y, Shigematsu N. Step section preparation of transbronchial lung biopsy. Significance in the diagnosis of diffuse lung disease. *Chest* 1991;100:959-62.
79. Woge MJ, Ryu JH, Bartholmai BJ, Yi ES. Cicatricial organizing pneumonia: a clinicopathologic and radiologic study on a cohort diagnosed by surgical lung biopsy at a single institution. *Hum Pathol* 2020;101:58-63.
80. Beasley MB, Franks TJ, Galvin JR, Gochuico B, Travis WD. Acute fibrinous and organizing pneumonia: a histological pattern of lung injury and possible variant of diffuse alveolar damage. *Arch Pathol Lab Med* 2002;126:1064-70.
81. Bhatti S, Hakeem A, Torrealba J, McMahon JP, Meyer KC. Severe acute fibrinous and organizing pneumonia (AFOP) causing ventilatory failure: successful treatment with mycophenolate mofetil and corticosteroids. *Respir Med* 2009;103:1764-7.
82. Lee SM, Park J-J, Sung SH, et al. Acute fibrinous and organizing pneumonia following hematopoietic stem cell transplantation. *Korean J Intern Med* 2009;24:156-9.
83. Lu J, Yin Q, Zha Y, et al. Acute fibrinous and organizing pneumonia: two case reports and literature review. *BMC Pulm Med* 2019;19:141.
84. Stover DE, Mangino D. Macrolides: a treatment alternative for bronchiolitis obliterans organizing pneumonia? *Chest* 2005;128:3611-7.
85. Lee J, Cha SI, Park TI, Park JY, Jung TH, Kim CH. Adjunctive effects of cyclosporine and macrolide in rapidly progressive cryptogenic organizing pneumonia with no prompt response to steroid. *Intern Med* 2011;50:475-9.
86. Koinuma D, Miki M, Ebina M, et al. Successful treatment of a case with rapidly progressive bronchiolitis obliterans organizing pneumonia (BOOP) using cyclosporin A and corticosteroid. *Intern Med* 2002;41:26-9.
87. Shitenberg D, Fruchter O, Fridel L, Kramer MR. Successful rituximab therapy in steroid-resistant, cryptogenic organizing pneumonia: a case series. *Respiration* 2015;90:155-9.
88. Dimala CA, Patel U, Lloyd B, et al. A case report of steroid-resistant cryptogenic organizing pneumonia managed with intravenous immunoglobulins. *Case Rep Pulmonol* 2021;2021:9343491.

Copyright © 2022 Massachusetts Medical Society.